

Manchester Dysmorphology Course
15th October 2026

Syndromes of the Ras-MAPK and PI3K pathways

Emma MM Burkitt Wright

Consultant Clinical Geneticist, Manchester Centre for Genomic Medicine

Honorary Senior Clinical Lecturer, University of Manchester

NHS Manchester University NHS Foundation Trust

MANCHESTER 1824 The University of Manchester

Overview

- ‘the’ Ras-MAPK pathway
  - Germline conditions: NF1, Noonan syndrome, related conditions including CFC syndrome, Costello syndrome
  - Early somatic, mosaic conditions
  - Somatic variation – cancer, non-malignant presentations
- ‘the’ PI3K pathway – also see SDH’s presentation 16/10/26
  - Germline conditions are rarer
  - Early somatic, mosaic conditions are characteristic
  - Somatic variation – cancer, non-malignant presentations
- Treatments?

Germline disorders of the Ras-MAPK pathway

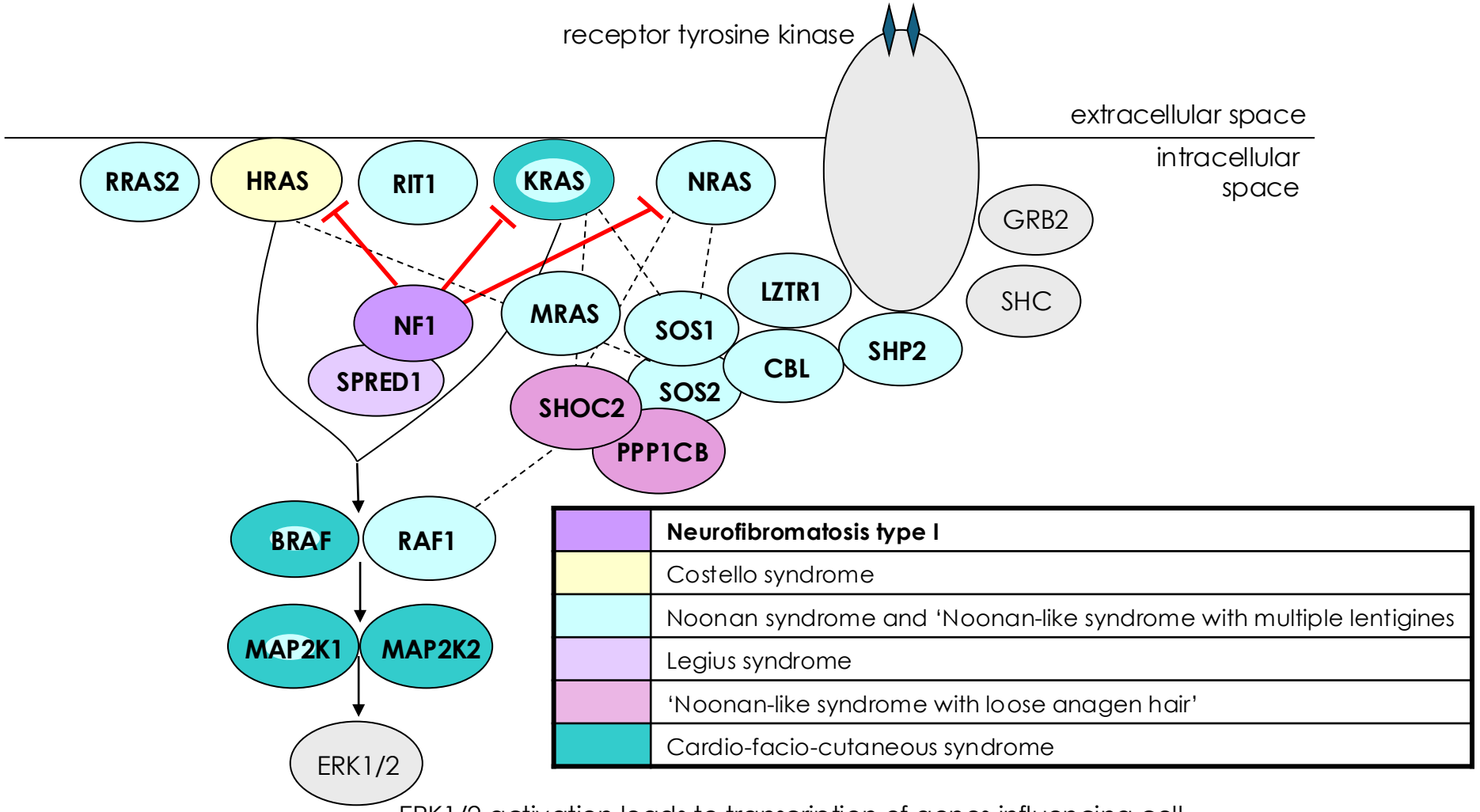

ERK1/2 activation leads to transcription of genes influencing cell proliferation, growth and other processes in both nucleus and cytosol

Manchester University NHS Foundation Trust

NB Ras proteins also play roles in signal transduction down multiple other pathways, including the PI3K pathway, and interactions and feedback loops are complex

Common features across Ras-MAPK pathway disorders

- Short stature, macrocephaly
- Normal or high birthweight
- Developmental delay (global or SLD)
- Behavioural phenotypes?
- Congenital heart disease, HCM or arrhythmia
- Cutaneous features
- Tumour predisposition?

Ras-MAPK dysmorphology can be straightforward, or (very) difficult!

Ras-MAPK disorders timeline

clinical		molecular	
1882	**NF1**	1990	*NF1*
1968	**Noonan**	2001	*PTPN11* …
1977	**Costello**	2005	*HRAS*
1986	**CFC**	2006	*BRAF, KRAS, MEK1/2* …

‘Gene discovery’ timeline

cancer	1982	***HRAS***
germline	1990 2001 2005	***NF1*** ***PTPN11*** ***HRAS***
early somatic	2012	***PIK3CA etc***
other somatic	2020’s	too many to mention!
…		

NF1 and Noonan syndrome are some of the commonest germline disorders: why?

- NF1 affects1 in 2000 births, 1 in 4000 prevalence; 50% *de novo*
- *NF1* is a large gene, so many ways to lose function…?
- Deleterious changes in *NF1* show a high penetrance

- Noonan syndrome – gain of function variants, predominantly in *PTPN11*, highly clustered

- Positive selection/growth advantage for cells with mutated alleles: ***selfish spermatogonial selection***

Maher et al, 2018 (Goriely and Wilkie labs)

NF1 and Legius syndrome





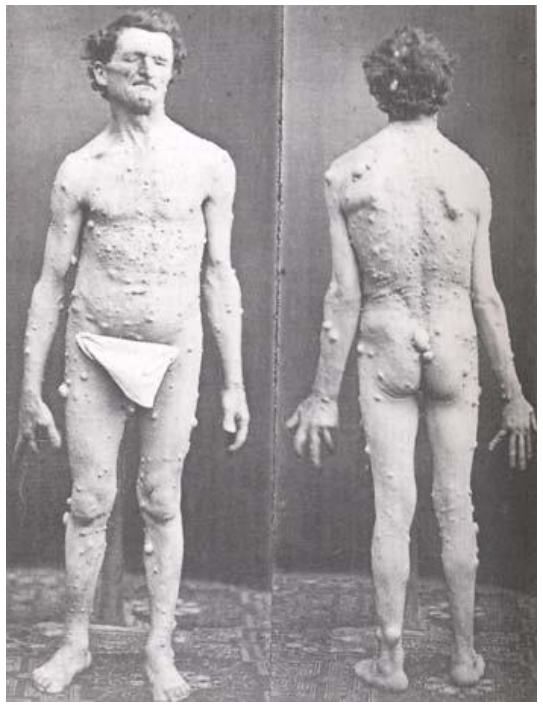

SCIENCE, VOL. 249 13 JULY 1990

Type 1 Neurofibromatosis Gene: Identification of a Large Transcript Disrupted in Three NF1 Patients

MARGARET R. WALLACE, DOUGLAS A. MARCHUK, LONE B. ANDERSEN, ROXANNE LETCHER, HANA M. ODEH, ANN M. SAULINO, JANE W. FOUNTAIN, ANNE BRERETON, JANE NICHOLSON, ANNA L. MITCHELL, BERNARD H. BROWNSTEIN, FRANCIS S. COLLINS

VOLUME 39 | NUMBER 9 | SEPTEMBER 2007 nature genetics

Germline loss-of-function mutations in *SPRED1* cause a neurofibromatosis 1–like phenotype

Hilde Brems[1,9], Magdalena Chmara[1,2,9], Mourad Sahbatou[3,9], Ellen Denayer[1], Koji Taniguchi[4], Reiko Kato[4], Riet Somers[1,5], Ludwine Messiaen[6], Sofie De Schepper[7], Jean-Pierre Fryns[1], Jan Cools[1,5], Peter Marynen[1,5], Gilles Thomas[3,8], Akihiko Yoshimura[4] & Eric Legius[1]

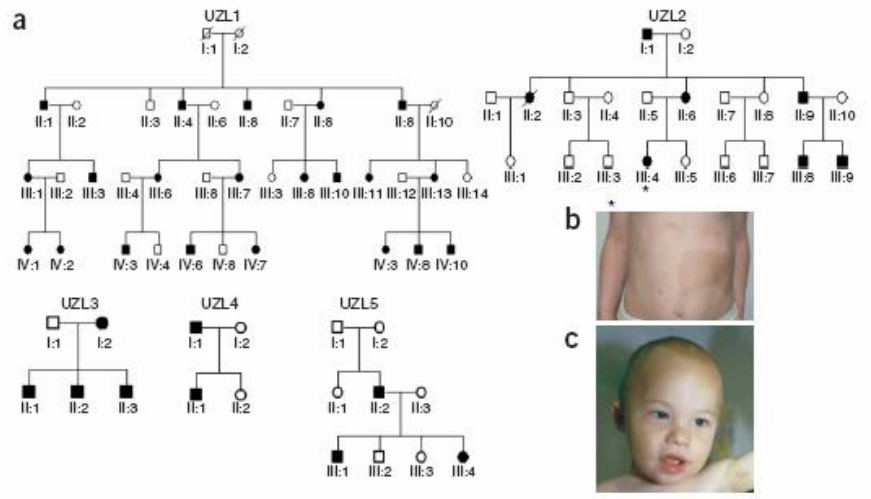

NF1: highly variable

- Cutaneous manifestations in nearly all +/- neurobehavioural features (60%, often subclinical?)
- Malignancy risk
- Wide variety of rare manifestations
  - Congenital anomalies, large plexiforms, rare tumours
- Reduced life expectancy, with a peak of early deaths: median survival reduced by 7 years

Evans et al, 2011 PMID: 21694737

NF1: Natural History

MAJOR DEFINING FEATURES	CAL spots only?	CAL spots (± freckles) + Lisch nodules	CAL spots (± freckles) + Lisch Nodules + Dermal NFs



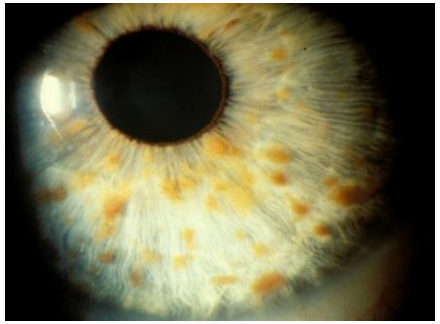



5 years... 15 years.... Adults

Manchester University NHS Foundation Trust

Original slide courtesy of Sue Huson

Early complications of NF1

- Occasional prenatal features (increased nuchal measurement?)
- **Plexiforms evident at birth will often be very severe – prioritise referral for consideration of treatment**
- **Optic pathway glioma – early presentation may be associated with poorer visual prognosis**
- **Juvenile myelomonocytic leukaemia**
- **MPNST is rare in childhood, but can occur at any age**
- **Embryonal tumours (especially rhabdomyosarcoma)**

- Many children will have CAL as the sole presenting feature of NF1

Additional manifestations of NF1

- Tumours:
  - Low grade glioma, other CNS tumours
  - **Lifelong risk of malignant peripheral nerve sheath tumour (MPNST)**
  - **Phaeochromocytoma**, gastrointestinal stromal tumour…
  - Increased risk of other tumours (**breast**, ?thyroid, ??colorectal)
- **Short stature**, precocious (or delayed) puberty
- Skeletal problems: tibial pseudarthrosis, scoliosis…
- **Learning disability, ADHD** (particularly inattentive subtype), **autistic spectrum features**
- Cardiovascular disease

CHILDREN'S TUMOR FOUNDATION
ENDING NF THROUGH RESEARCH

A diagnosis of NF1 can be given if an individual has two or more of the following manifestations.



Optic pathway glioma (tumor of the visual pathway)

Two or more Lisch nodules or two or more choroidal abnormalities

Freckling in axilla (armpit) or groin*

Six or more café-au-lait macules* (brown skin spots)
- » greater than 5mm in pre-pubertal children
- » greater than 15mm in post-pubertal individuals

Two or more neurofibroma tumors of any type, or one plexiform neurofibroma

A distinctive osseous lesion such as: sphenoid dysplasia; anterolateral bowing of tibia (tibial dysplasia); or pseudarthrosis of a long bone

ctf.org



A pathogenic *NF1* gene variant**

***Additional Genetic Criteria Updates:*

- *The term "mutation" is no longer accepted; pathogenic variant is now the preferred term.*
- *Genetic analysis is not REQUIRED for diagnosis but may allow for an earlier diagnosis.*
- *Genetic analysis ALONE is not sufficient to diagnose NF1 - diagnosis requires a second diagnostic feature of NF1.*

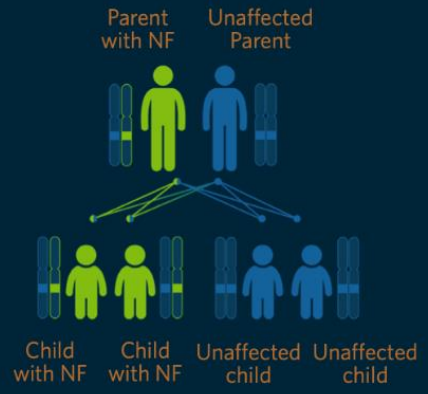

A parent with NF1 based on diagnostic criteria

**At least one of the two pigmentary findings (café-au-lait macules or freckling) should be bilateral.*

Legius et al, 2021

Molecular genetic testing for NF1

- R222 in NHS genomic test directory
  - Requestable by genetics, dermatology, neurology, paediatrics
- DNA sequencing: all exons of *NF1* and *SPRED1* + recurrently observed splice variants +
  MLPA for copy number analysis (*NF1*, flanking genes)
- R376 'segmental/mosaic or atypical NF1'
  - RNA-based testing, requestable by genetics, neurology

- RNA+MLPA: > 95% of bona fide constitutional NF1 should have a molecular variant identified
- *Recently observed significantly lower rate than this – current variant classification algorithm needs work!*

Evans et al, 2016 PMID: 27322474

A subtype of NF1: *NF1* whole gene deletion

- ~5% of unselected patients with NF1 (Cnossen 1997, Rasmussen 1998)
- Distinct phenotype of type 1 WGD
  - facial dysmorphism
  - some learning difficulties in ~ all affected people
  - normal / tall stature: *RNF135* co-deletion

    (haploinsufficiency for *RNF135* produces an overgrowth syndrome)
  - large burden of dermal neurofibromas
  - higher tumour risk

Other *NF1* whole gene deletions

- Type II deletions are smaller, and often mosaic – milder phenotype, neurofibroma burden variable
- Type III deletions are a mixed bag, and include patients with larger deletions:
  - May have more severe LD
  - Additional medical or developmental problems
  - NF1 may be subject to diagnostic overshadowing/compound presentation (eg babies with delayed development or congenital anomalies: incidental finding on microarray – or is it?)

Mosaicism: segmental NF1

- common!
- Segmental: usually much more limited features than generalised NF1 – may be skin manifestations only (NB ascertainment bias!)
- Under-recognised
  - May well be only affected person in the family
  - May well be no medical/developmental associated features
- Testing of *NF1* in blood will not usually reveal a variant

NF1 differential diagnosis

- Legius syndrome – CAL, macrocephaly
- Noonan syndrome and other germline Ras-MAPK pathway disorders

- Constitutional mismatch repair deficiency syndrome – may result in *bona fide* NF1-driven features
- Multiple lipomatosis
- Mosaic phenotypes (NF1, Legius, *KRAS*…)

- Pigmentary phenotypes/mosaicism

Differentiating NF1 from Legius syndrome (Legius et al, 2021)

NF1
1 in 2000 births
50% *de novo*

Table 1. Revised diagnostic criteria for neurofibromatosis type 1 (NF1).

A: The diagnostic criteria for NF1 are met in an individual who does not have a parent diagnosed with NF1 if two or more of the following are present:

- Six or more café-au-lait macules over 5 mm in greatest diameter in prepubertal individuals and over 15 mm in greatest diameter in postpubertal individuals[a] (Supplementary Fig. 6)
- Freckling in the axillary or inguinal region[a] (Supplementary Fig. 7)
- Two or more neurofibromas of any type *or* one plexiform neurofibroma (Supplementary Fig. 8a, b)
- Optic pathway glioma (Supplementary Fig. 9)
- Two or more iris Lisch nodules identified by slit lamp examination or two or more choroidal abnormalities (CAs)—defined as bright, patchy nodules imaged by optical coherence tomography (OCT)/near-infrared reflectance (NIR) imaging (Supplementary Fig. 10a, b)
- A distinctive osseous lesion such as sphenoid dysplasia,[b] anterolateral bowing of the tibia, or pseudarthrosis of a long bone (Supplementary Fig. 11)
- A heterozygous pathogenic *NF1* variant with a variant allele fraction of 50% in apparently normal tissue such as white blood cells

B: A child of a parent who meets the diagnostic criteria specified in A merits a diagnosis of NF1 if one or more of the criteria in A are present

[a]If only café-au-lait macules and freckling are present, the diagnosis is most likely NF1 but exceptionally the person might have another diagnosis such as Legius syndrome. At least one of the two pigmentary findings (café-au-lait macules or freckling) should be bilateral.
[b]Sphenoid wing dysplasia is not a separate criterion in case of an ipsilateral orbital plexiform neurofibroma.

Legius syndrome
1 in 75000 births?
Usually inherited

May have short stature

Table 2. Diagnostic criteria for Legius syndrome.

A: The diagnostic criteria for Legius syndrome are met in an individual who does not have a parent diagnosed with Legius syndrome if the following CRITERIA are present:

- Six or more café-au-lait macules (Supplementary Fig. 12) bilaterally distributed and no other NF1-related diagnostic criteria except for axillary or inguinal freckling[a]
- A heterozygous pathogenic variant in *SPRED1* with a variant allele fraction of 50% in apparently normal tissue such as white blood cells

B: A child of a parent who meets the diagnostic criteria specified in A merits a diagnosis of Legius syndrome if one or more of the criteria in A are present

[a]The presence of fewer than six café-au-lait spots does not exclude Legius syndrome.

Legius syndrome is a mild condition, but recent/incomplete recognition: **cancer risk?**
(Frone M, Stewart D et al, unpublished data from ongoing NIH Rasopathies natural history study)

Severe segmental presentations: NF1 or not?

cervical root neurofibromas, aortic coarctation, scoliosis and plexiform neurofibroma of coeliac plexus (under observation)
Vasculopathy – digital ischaemia/severe Raynaud's

Lifelong spotty pigmentation around left shoulder and elsewhere

Café-au-lait patches on lower limbs and lumbar region

Progressive problems with mobility, sensory and motor disturbance around right ankle

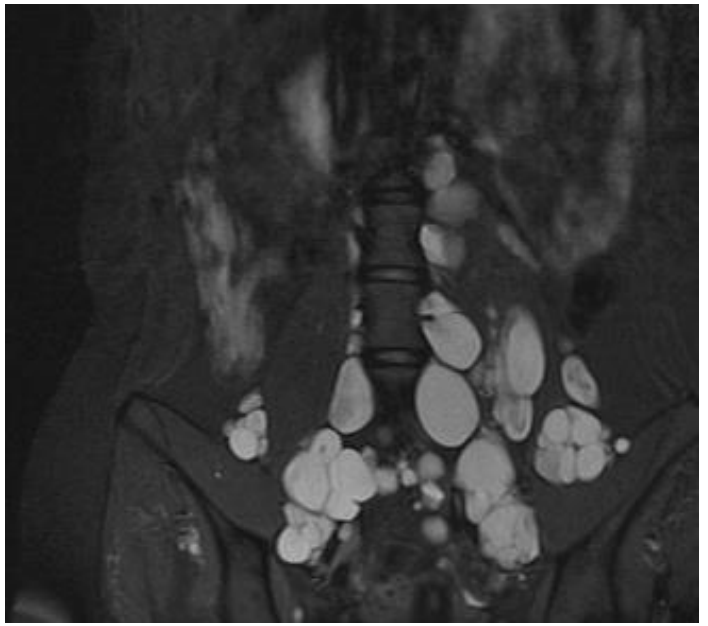

NF1 RNA testing in blood – no abnormalities detected
NF1 RNA testing in melanocytes from pigmented spots – **no variants found**

Further testing on melanocytes

- *KRAS* c.35G>A p.(Gly12Asp), apparently heterozygous, in all melanocyte cultures of these two patients

- Compatible with diagnosis of KRAS-associated neurocutaneous disorder

- Mosaic presentation, no appreciable recurrence risk to their children

Noonan syndrome

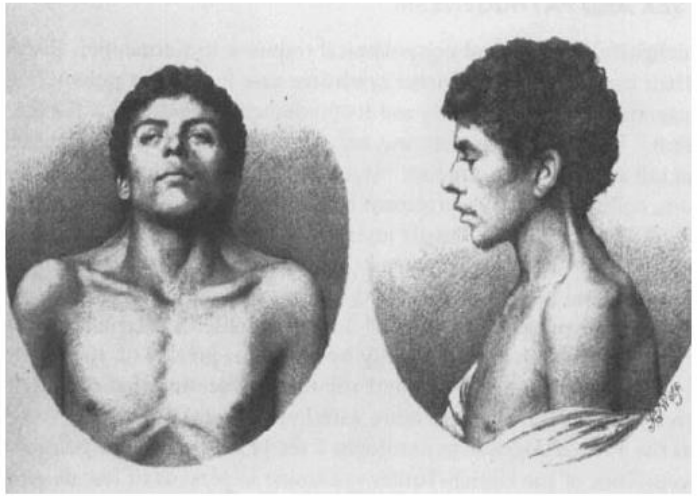

Kobylinski (1883) in Opitz & Pallister (1979)
AJMG **4**: 333-343





Genetically heterogeneous: *PTPN11* variants in 50%, many other genes

Short stature

Congenital heart disease: pulmonary stenosis

Characteristic appearance..?

Cryptorchidism

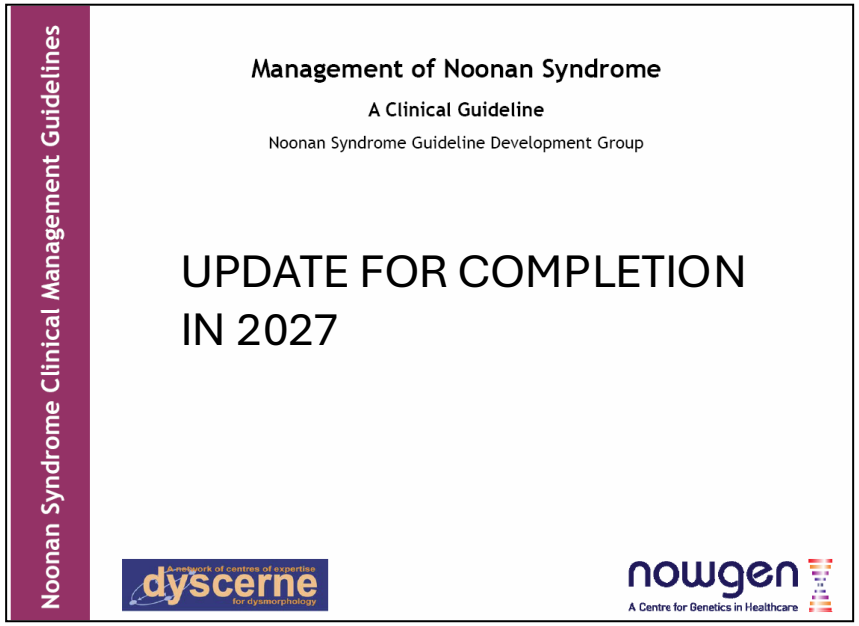

Noonan syndrome

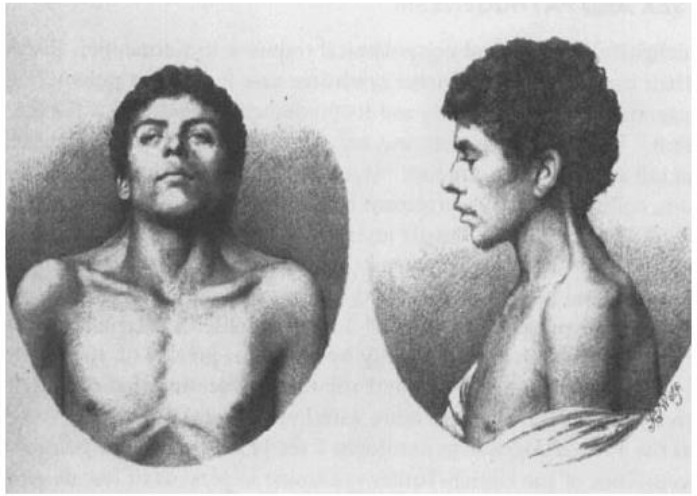

Kobylinski (1883) in Opitz & Pallister (1979)
AJMG **4**: 333-343





Genetically heterogeneous: *PTPN11 mutations* in 50%, many other genes

Hypertrophic cardiomyopathy

Lymphatic failure

Neurobehavioural features

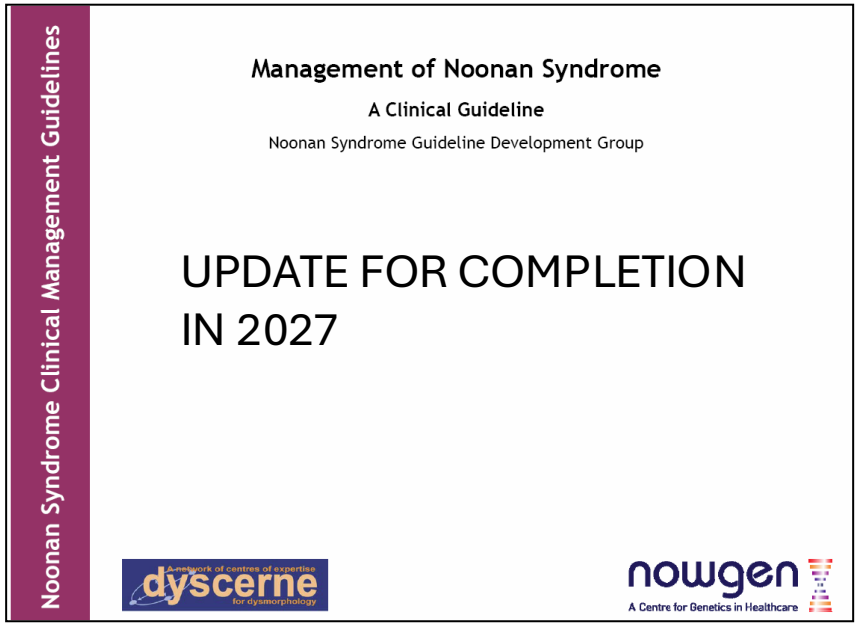

What is Noonan syndrome?

- Mainly AD
  - Recessive *LZTR1* variants account for a small proportion
- 2/3 de novo
- Multiple different genes

- Continuum with CFC syndrome
  - ‘the Noonan syndrome spectrum’

What is the Noonan syndrome spectrum?

- Classical NS
- Noonan syndrome with multiple lentigines
- Noonan-like syndrome with loose anagen hair (Mazzanti syndrome)
- CBL-associated syndrome
- CFC syndrome

- Costello syndrome?
- Legius syndrome?
- NF1?

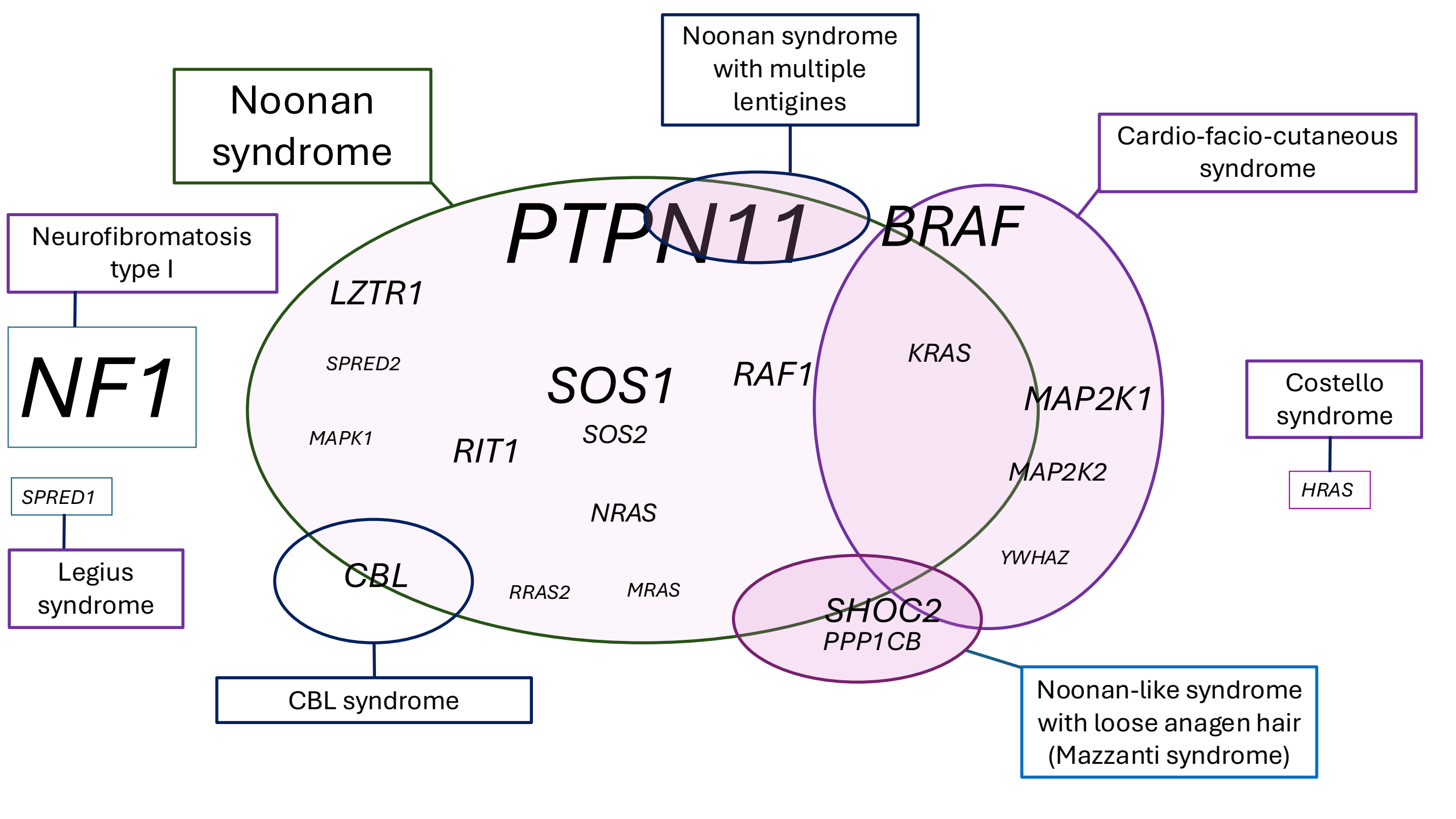
Noonan syndrome
Noonan syndrome with multiple lentigines
Cardio-facio-cutaneous syndrome
Neurofibromatosis type I
NF1
SPRED1
Legius syndrome
Costello syndrome
HRAS
CBL syndrome
Noonan-like syndrome with loose anagen hair (Mazzanti syndrome)
PTPN11
BRAF
LZTR1
SPRED2
SOS1
RAF1
KRAS
MAP2K1
MAPK1
RIT1
SOS2
MAP2K2
NRAS
YWHAZ
CBL
RRAS2
MRAS
SHOC2
PPP1CB



PTPN11

Noonan syndrome



SOS1

RESEARCH ARTICLE

AMERICAN JOURNAL OF medical genetics PART A

The Face of Noonan Syndrome: Does Phenotype Predict Genotype

Judith E. Allanson,[1,2]* Axel Bohring,[3] Helmuth-Guenther Dorr,[4] Andreas Dufke,[5] Gabrielle Gillessen-Kaesbach,[6] Denise Horn,[7] Rainer König,[8] Christian P. Kratz,[9] Kerstin Kutsche,[10] Silke Pauli,[11] Salmo Raskin,[12] Anita Rauch,[13] Anne Turner,[14] Dagmar Wieczorek,[15] and Martin Zenker[16]

Am J Med Genet Part A 152A:1960–1966.



RAF I

Noonan syndrome



KRAS

RESEARCH ARTICLE

AMERICAN JOURNAL OF medical genetics PART A

The Face of Noonan Syndrome: Does Phenotype Predict Genotype

Judith E. Allanson,[1,2*] Axel Bohring,[3] Helmuth-Guenther Dorr,[4] Andreas Dufke,[5] Gabrielle Gillessen-Kaesbach,[6] Denise Horn,[7] Rainer König,[8] Christian P. Kratz,[9] Kerstin Kutsche,[10] Silke Pauli,[11] Salmo Raskin,[12] Anita Rauch,[13] Anne Turner,[14] Dagmar Wieczorek,[15] and Martin Zenker[16]

Am J Med Genet Part A 152A:1960–1966.

Noonan-like syndrome with multiple lentigines
(formerly LEOPARD syndrome)

Lentigines
ECG abnormalities
Ocular hypertelorism
Pulmonary stenosis
Abnormal genitalia
Retarded growth – taller than NS!
Deafness

Mutations in *PTPN11* (large majority)
RAF1 and *BRAF* (rare); other genes maybe…

CFC syndrome

- ***BRAF* most common gene implicated**
- Polyhydramnios and macrosomia
- Cardiomyopathy, cardiac anomalies
- Poor feeding (may be OK initially then deteriorate)
- Epilepsy (may be severe); learning disability

- May have normal heart and skin, and unremarkable facial appearance
- Structural brain anomalies (*BRAF, MAP2K1*), contractures (*MAP2K1*)
- *BRAF*-related neurodevelopmental disorder, epilepsy prominent

CFC syndrome

CAN HAVE NORMAL HEART, WITH UNREMARKABLE FACIAL AND ECTODERMAL FEATURES

- ***BRAF* most common gene implicated**
- Polyhydramnios and macrosomia
- Cardiomyopathy, cardiac anomalies
- Poor feeding (may be OK initially then deteriorate)
- Epilepsy (may be severe); learning disability

- May have normal heart and skin, and unremarkable facial appearance
- Structural brain anomalies (*BRAF, MAP2K1*), contractures (*MAP2K1*)
- *BRAF*-related neurodevelopmental disorder, epilepsy prominent

CFC syndrome



BRAF



MAP2K1

MAP2K2

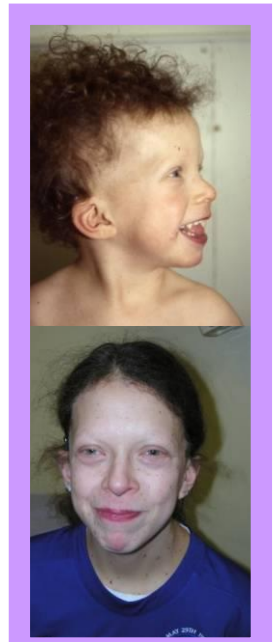

KRAS: Noonan or CFC syndrome

- ***Germline variants rare***

- ***More severe phenotype than 'average' NS***
  - ***sometimes mistaken for Costello syndrome***

- ***CFC may be most appropriate clinical description***
  - ***but ectodermal features are often not prominent***

- ***LD***
- ***Significant HCM and mortality in some***
- ***Most de novo, a couple of milder alleles reported***

SHOC2/PPP1CB: Mazzanti syndrome

(90% = *SHOC2* p.Ser2Gly)

- Feeding difficulties, several PEG fed in early childhood
- Range of cardiac anomalies
- Short stature, high prevalence of GHD
- Ectodermal features, autoimmune disease

Costello syndrome







- ***HRAS* variants (80% = p.(Gly12Ser))**
- Polyhydramnios and macrosomia
- Neonatal hypoglycaemia
- Cardiomyopathy, cardiac anomalies
- Poor feeding
- Excess skin on hands and feet, ulnar deviation
- Learning disability
- High tumour risk, embryonal rhabdomyosarcoma



HRAS

Costello syndrome

Diagnostic features: specific to Costello syndrome?

Neonatal atrial arrhythmia: *RAF1*

Ulnar deviation: *BRAF, other CFC*

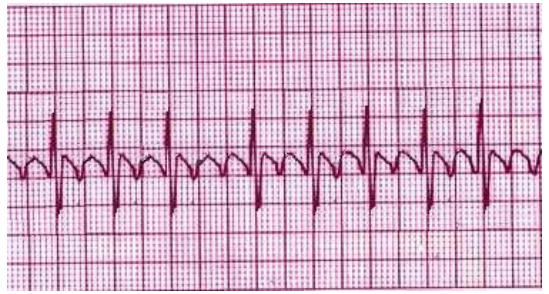

Embryonal rhabdomyosarcoma: *SOS1*

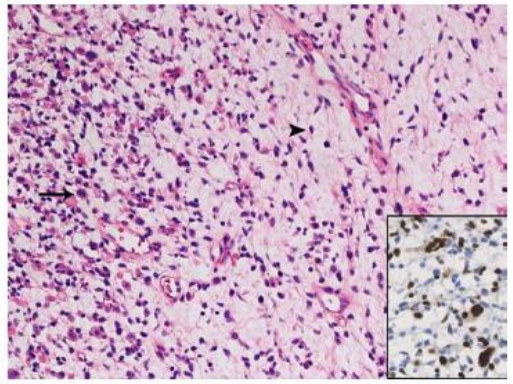

Figure 1. Histology of the embryonal rhabdomyosarcoma in the patient with NS showing primitive spindle cells (arrowhead) and scattered rhabdomyoblasts (arrow) with an eosinophilic cytoplasm (H&E, magnification ×100). Inset: nuclear positivity for myogenin (brown).

Nasal papilloma: *SHOC2*

HRAS mutations in cancer and Costello syndrome:

p.(Gly12Val) commonest in cancer

Germline p.(Gly12Val) mutations rare in Costello syndrome, cause neonatal lethal phenotype:

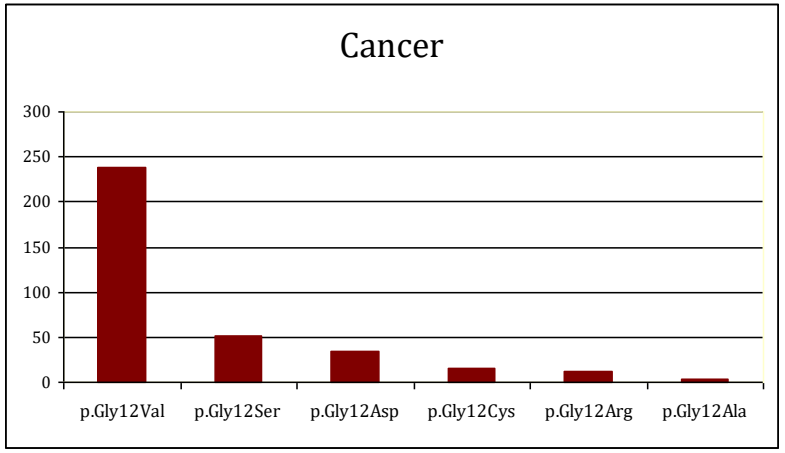

Numbers taken from www.**sanger**.ac.uk/perl/genetics/CGP/**cosmic**

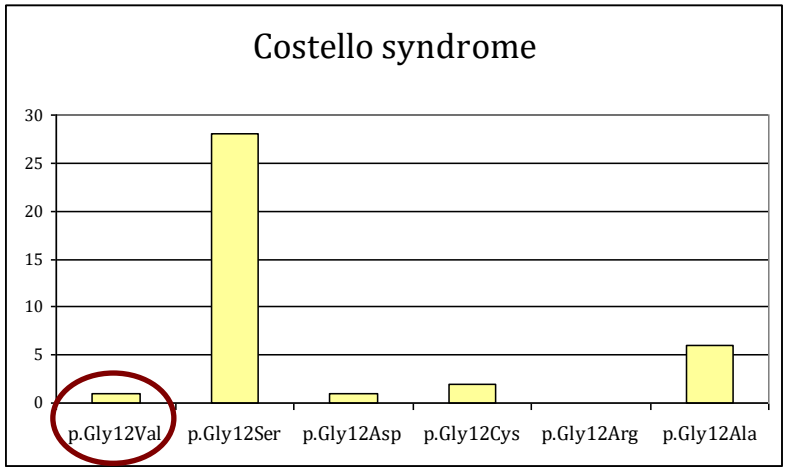

BRAF mutations in CFC and in tumours:

Not quite mutually exclusive, but nearly so -

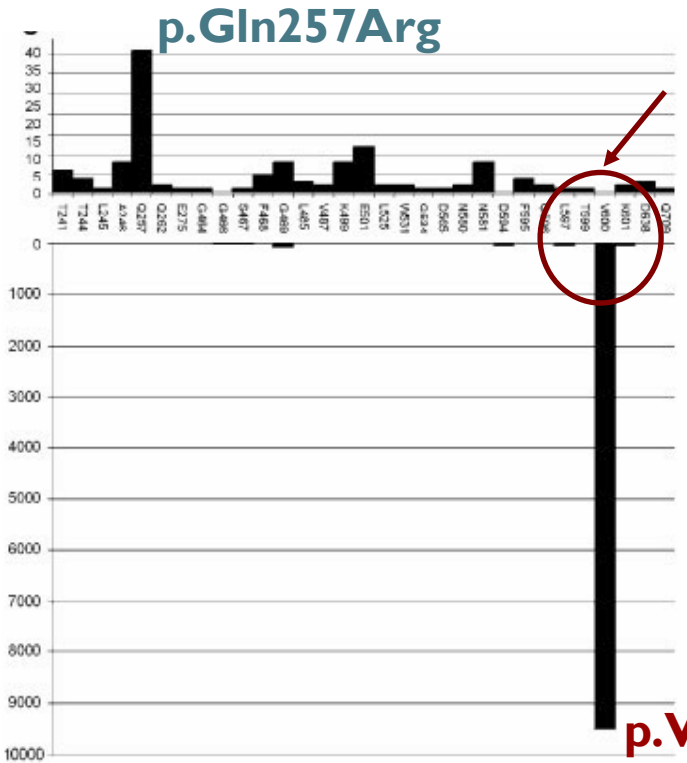

Mechanisms of action appear complex: not purely related to kinase activity?

Dimerisation with RAF1 (=CRAF) may be important

p.Val600Glu: extreme effects on downstream pathway activity, embryonic lethal in mouse

Sarkozy et al (2009). *Hum Mutation* **30**: 695-702

Survival across the Ras-MAPK pathway: neurodevelopment, cancer, heart issues?

- ***BRAF, MAP2K1*: often severely affected, but NB occasional NS/multiple lentigines syndrome presentations**
- ***HRAS*: often better than initial fears; growing spectrum of recognised mild and severe *HRAS* variants**
- ***KRAS, MAP2K2*: small numbers, a very few families reported with vertical transmission**
- ***SHOC2*: variable; apparently *de novo ~100%***
- ***PTPN11, SOS1, CBL, (NRAS), NF1, SPRED1*: variable, vertical transmission well known**

Heart disease in NS/CFC/CS

Structural defects:

- Common, especially pulmonary stenosis and ASD
- Wide variety of lesions described

Hypertrophic cardiomyopathy:

- Certain genes confer higher risk: eg *RAF1*, *RIT1*, *HRAS*
  - **but** NB higher prevalence of mutations in other genes (*PTPN11* still accounts for highest proportion)

Arrhythmia: high risk in

- *HRAS*
- *RAF1* (Kobayashi T et al (2010). *Hum Mutat* **31**: 284-94)

Cancer risk across the Ras-MAPK pathway

- ***Costello syndrome:*** *HIGH RISK* (15% in childhood)

- ***Noonan syndrome:*** *MODESTLY ELEVATED?*
- ***CFC syndrome:*** *PROBABLY LOWER THAN NS?*

- ***NF1:*** *ELEVATED*
- ***Legius syndrome:*** *MODESTLY ELEVATED??*

What are the syndromes of the PI3K pathway? Too many to mention!

- ***PIK3CA*-related overgrowth spectrum**
- *PIK3R2* - related (megalencephaly and other) presen
- *AKT1* - Proteus syndrome
- *PTEN* - related syndromes
- *TSC1/2* - tuberous sclerosis
- *PIK3CD* - related immune presentations, *PIK3C2A* - related oculoskeletodental syndrome…

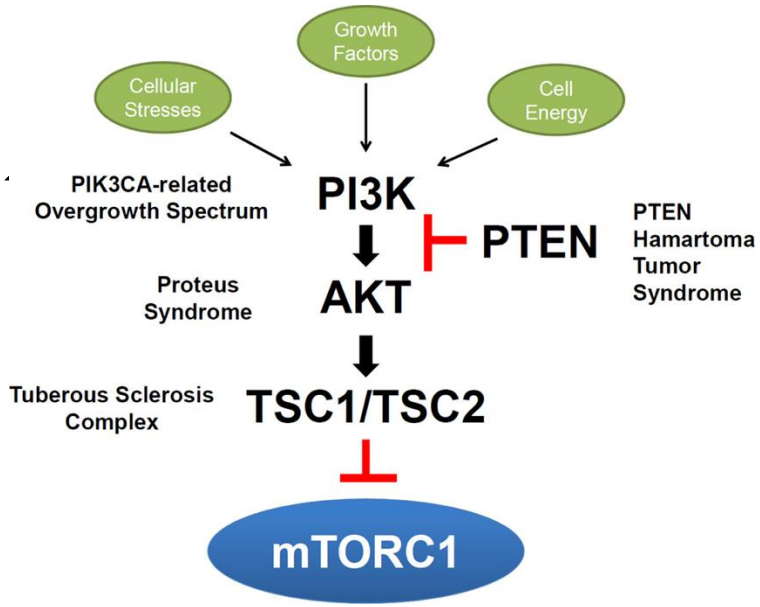

The PI3K pathway – interplay with the Ras-MAPK pathway

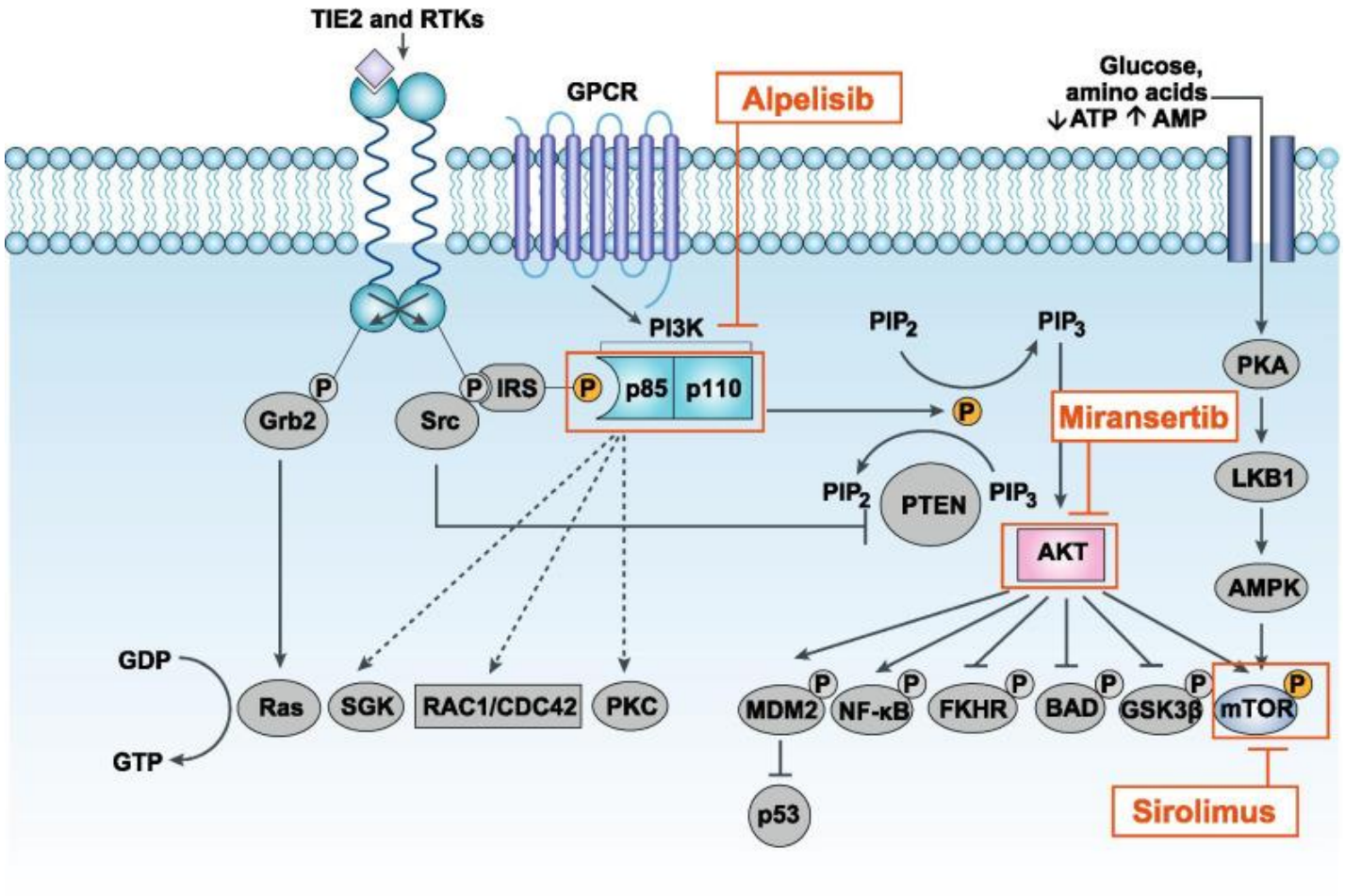

Canaud et al, Orphanet J Rare Dis 2021

PIK3CA-related overgrowth syndrome: a mosaic disorder – or group of disorders



Spectrum of Overgrowth in Patients with Activating PIK3CA Mutations

Patient C1 showing (**A**)&(**B**) Lower extremity overgrowth with a paucity of facial adipose tissue at ages 12 months and 7 years progressing to (**C**) Massive leg overgrowth with lack of upper body adipose tissue at 37 years old, by which time left above knee amputation had been undertaken. (**D**) Right foot overgrowth at 35 years old (**E**) Feet at 35 years showing overgrowth, cutaneous syndactyly of the left foot and rotational deformity of the right foot .(**F**) and (**G**). Patient N7 showing his leg status post debulking surgery and massive overgrowth of the left foot, which was partially amputated. (**H**) and (**I**) Patient N99 showing more limited overgrowth confined to several rays of the feet. Informed consent to publish photographs was obtained from the identifiable patient in this figure.

- Archetypal PIK3CA variants are not seen in the germline: too dysregulating to be compatible with embryonic development?

Lindhurst et al, 2012

Defining the PIK3CA-related overgrowth spectrum

- *Too many different names and clinical presentations!*
- Need clarity for understanding natural history and potential therapy

- Good example in favour of Biesecker's dyadic nomenclature

- …but we also need to take into account
  - Specific variant allele
  - Tissue distribution (some descriptive condition names help with this)
  - Variant allele frequency?

Treatment

- Surgery for overgrowth/plexiform neurofibroma
- Standard/tailored medical care for complications

- Supportive care/ therapies input for neurobehavioural sequelae

- **Targeted pharmaceuticals**
  - **Whom to treat?**
    - **Treatable manifestations?**
    - **Severe situations?**

Targeted treatment for the Ras-MAPK pathway: MEK (MAP2K1/2) inhibition

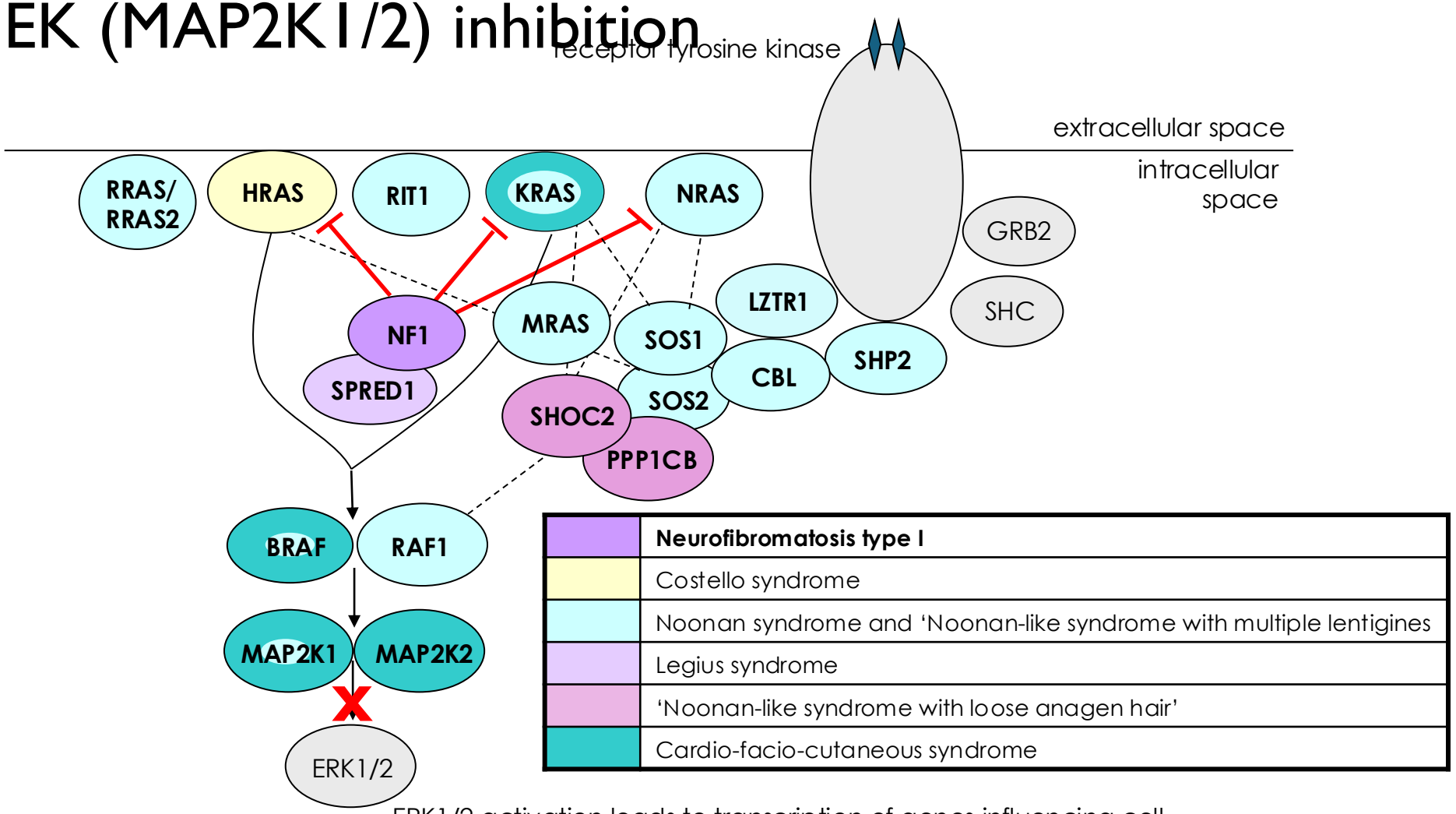

ERK1/2 activation leads to transcription of genes influencing cell proliferation, growth and other processes in both nucleus and cytosol

NB Ras proteins also play roles in signal transduction down multiple other pathways, including the PI3K pathway, and interactions and feedback loops are complex

MEK inhibition for Ras-MAPK pathway disorders

- Selumetinib is NHS NICE approved for treatment of inoperable plexiform neurofibroma in children with NF1 – new sprinkle formulation makes younger treatment possible
- Trametinib been used in individual situations
  - Plexiforms where liquid formulation required
  - NF1-associated OPG refractory to other treatment
  - Lymphatic failure (central conducting lymphatic defects) and severe HCM in Noonan syndrome spectrum, Costello syndrome
  - Epilepsy in CFC syndrome?

MEK inhibition for Ras-MAPK pathway disorders

- Refractory HCM (infants) – compassionate use/ IFR
  - Bridge to heart transplant
  - mTOR inhibitors have also been used in rare patients in this context, given role of pAKT signalling in myocardial hypertrophy
- Lymphatic failure
  - Some have had a remarkable effect, others not

Targeted treatment for PIK3CA-related overgrowth

- Alpelisib is an inhibitor of PIK3CA

- Developed for treatment of *PIK3CA*-mutated cancers (eg breast cancer)

- Trial (EPIK-P2) ongoing in Europe (hasn't met primary endpoint), but has recently received FDA approval (accelerated in 2022, treatment approved for those 2 years and over), further trials planned

Summary

- Germline inherited conditions include Legius syndrome, 50% of NF1, ~30% of Noonan syndrome
- De novo germline presentations include 50% of NF1, 70% of Noonan, and nearly all Costello and CFC presentations
- Exclusively mosaic presentations, eg PROS, are underpinned by variants likely to be incompatible with germline development
  - Deep sequencing may be used to show variant allele frequencies down to eg 0.25%, need to test the right cell lineage!
- Positive selection for variant alleles may help to explain the high frequency of these conditions

Summary

- Don’t believe fundamental changes to a key protein will only be acting on one biochemical pathway
- Do believe that wider genomic and non-heritable factors will have interplay with a primary variant to determine an individual’s phenotype
- Still much to do in understanding phenotype and natural history (overcoming historical ascertainment biases and difficulties in making molecular diagnoses)
- Surprising elements of phenotype may prove amenable to treatment in the future, but one treatment won’t work for everyone

Acknowledgements

Bronwyn Kerr, international NSS consortium colleagues and others

All current and former NF1 team colleagues

Contact:

emma.burkitt-wright@mft.nhs.uk



NF1 manifestations warranting specialist MDT care:

2 sites, Manchester and Guy's NHSE HSS for complex NF1

- Malignant peripheral nerve sheath tumour (MPNST)
- Juvenile myelomonocytic leukaemia
- Symptomatic optic pathway glioma
- Phaeochromocytoma, other tumours (e.g. breast cancer)
- **Symptomatic** plexiform neurofibromas
- CNS glioma, cord compression, neurofibromatous neuropathy, multiple sclerosis, problematic epilepsy
- Tibial pseudarthrosis
- Whole gene deletion, other unusual phenotypes
- Counselling and molecular diagnosis for segmental NF1

NHS
Manchester University
NHS Foundation Trust

Which patients should be seen in the complex NF1 clinic?

- One or more complex criteria
- Children with significant plexiforms in whom selumetinib may be considered
- ***Non-emergency service*** **–** does not substitute for standard local pathways for emergency referral for eg cord compression, hydrocephalus etc (later referral in may be appropriate).
- ***Sarcoma pathways*** are variable, must meet the need for very prompt assessment re ?MPNST in people with NF1

How do we manage NF1?

- Stratified by manifestations/level of identified risk?
- 'Complex NF1' – review in complex service
  - Annual or biennial follow up for ongoing needs

- Paediatrics: at least annual paediatric review for all children with NF1 (hospital/community)
- Adults with no complex ongoing needs: primary care, signposting to Nerve Tumours UK helpline

Version 18. 01/19

Neurofibromatosis Type 1

Review Guidelines



Annual Review Recommended

At time of diagnosis, or possible diagnosis, ALL patients should be seen in a genetics department. Those with significant complications will be followed up as appropriate through the nationally-funded Complex NF1 Service. Annual review should be undertaken by a Community/District Paediatrician and GP throughout childhood, and by a GP in adulthood. Patients, paediatricians and GPs have telephone access to the NF Service in Genetic Medicine for NF-related concerns.

AGE	GENETICS APPOINTMENT	NF1 REVIEWS CARRIED OUT BY	VISION CHECKS
<6 & 50% risk	In first year and then at 2 and 5*[1].	Care coordinated by Genetics.	Symptom check at NF1 review
<8 affected	Confirmation of diagnosis & assessment. Genetic counselling for family.	GP and Community/ District Paediatrician. Liaison with NF service for complex cases.	At least annual with paediatric ophthalmologist.
8 – 15 affected	On request		Annual with optician/orthoptist
16—18 affected	Appointment for counselling re: adult complications and genetics	Care coordinated by GP.	Symptom check at NF1 review
>16 affected*[2]	On request		

*[1] **If no café au lait spots by 5 years, NF1 can be excluded in the majority of NF1 families.**
Mutation testing can be considered to confirm or exclude the diagnosis and clarify the need follow up

*[2] **Women aged 40—50 should be referred for annual mammography as per 'moderate risk' NICE guidelines.**

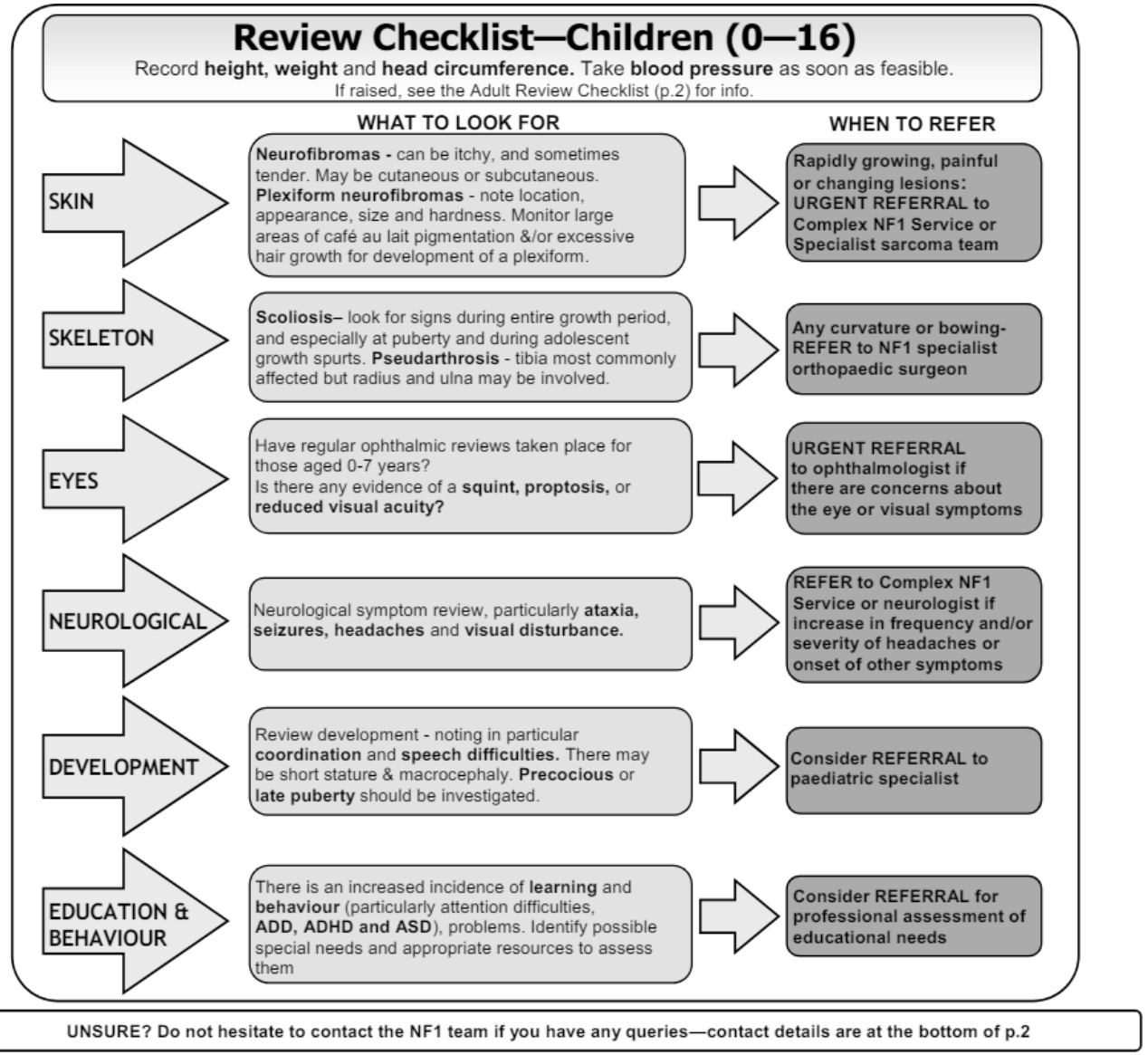

NHS
Manchester University
NHS Foundation Trust

https://www.mangen.co.uk/healthcare-professionals/clinical-genomic-services/nf1/

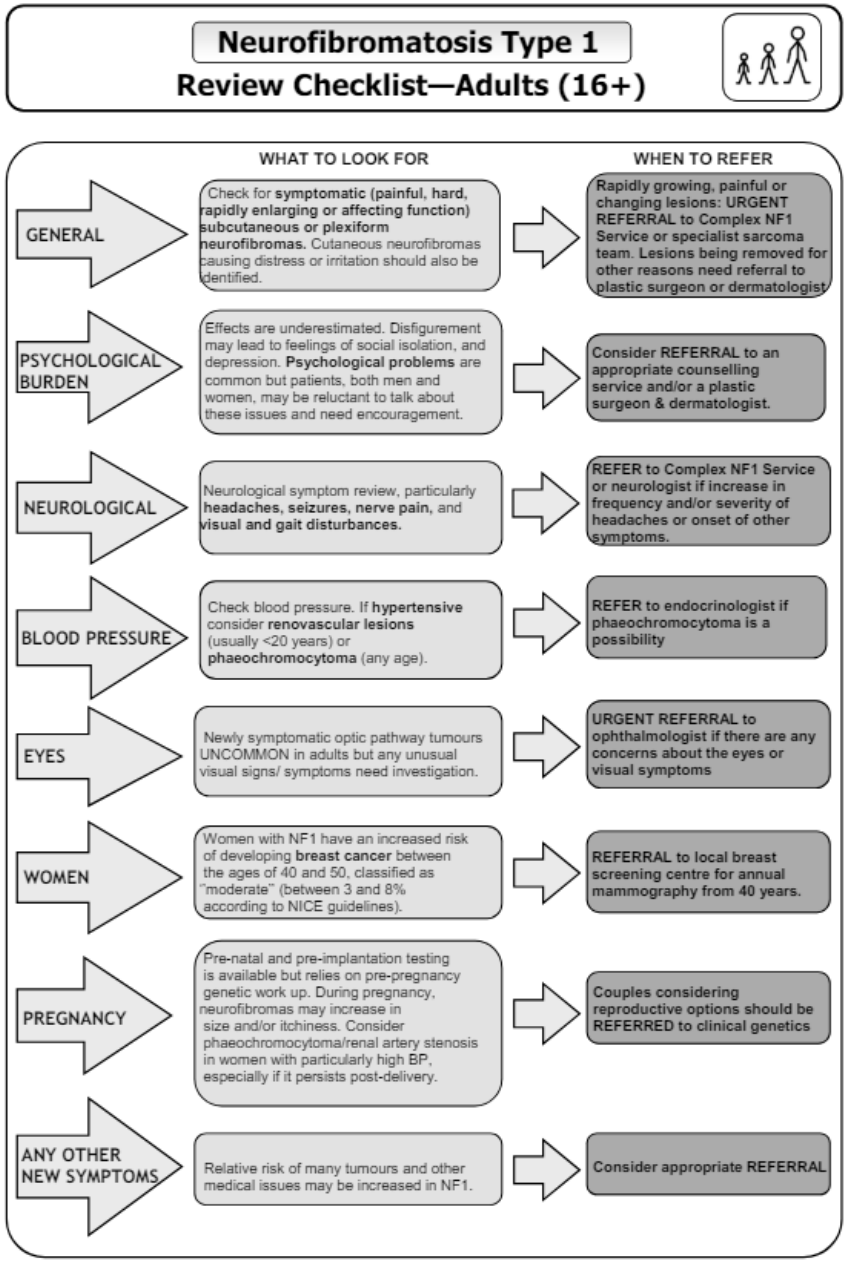

https://www.mangen.co.uk/healthcare-professionals/clinical-genomic-services/nf1/

ERN GENTURIS NF1 guidelines

Carton et al, 2023

Surveillance protocol for tumour screening/identification in individuals with NF1

	Surveillance	Interval	Age (years) / indication	Strength*	Refer^
Optic pathway glioma	Clinical assessment: 1. Visual assessment 2. Fundoscopy 3. Visual fields 4. Optic coherence tomography	1-3: At least yearly 4: When feasible	0 - 8	1. Strong 2. Strong 3. Moderate 4. Moderate	7.2 & 9.2 (rec. 1-4)
	Visual screening	Yearly	8 – transition adolescence to adult	Moderate	7.2 & 9.2 (rec. 5-6)
Brain or spine glioma	Patient history / Examination signs of brain tumours	Every visit	All ages	Moderate	7.3 & 9.3 (children) 7.4 & 9.4 (adults)
Plexiform neurofibroma	Clinical examination	Every visit	All ages	Moderate	7.5 & 9.5 (rec. 1-2)
	Whole body MRI	Once	Transition adolescence -adult	Weak	7.5 & 9.5 (rec. 3-4)
MPNST + ANNUBP	Clinical examination + history taking	Every visit	All ages	Strong	7.6 & 9.6 (rec. 1-2)
	Regional MRI combined with ^{18}FDG PET MRI or ^{18}FDG PET CT	On indication	Suspicion for malignancy	Moderate	7.6 & 9.6 (rec. 3)
Orbital & Periorbital Plexiform neurofibroma	Clinical assessment, refraction error, vision fields, ocular motility	Every visit	All ages	Strong	7.7 & 9.7 (rec. 1)
Cutaneous neurofibroma	Clinical examination	Every visit	All ages	Strong	7.8 & 9.8 (rec. 1)
Gastrointestinal stromal tumour	Clinical examination + history taking	Every visit	Adolescence and adults	Moderate	7.9 & 9.9 (rec. 1-2)
	Abdominal MRI or CT	On indication	Clinical suspicion of presence based on symptoms	Moderate	7.9 & 9.9 (rec. 4)
Phaeochromocytoma and paraganglioma	Biochemical screening	On indication	Raised blood pressure	Moderate	7.10 & 9.10 (rec. 2)
	Biochemical screening	On indication	Pregnant women Consider if elective surgery requiring general anaesthesia	Weak	7.10 & 9.10 (rec. 1 and 3)
Breast cancer	MRI	Yearly	30 - 50	Moderate	7.11 & 9.11 (rec. 2-3)
	Breast screening per national guideline for the general population		> 50	Moderate	7.11 & 9.11 (rec. 2-3)
Glomus tumours of the digits	Screening for symptoms and visual inspection	Every visit	All ages, clinical suspicion	Moderate (Age, weak)	7.12 & 9.12 (rec. 1-3)
Juvenile myelomonocytic leukaemia	As part of normal clinical routine: patient history and physical examination	Every visit	<12	Moderate	7.13 & 9.13 (rec. 1-2)
Psychosocial needs	Psychosocial wellbeing and neuropsychological functioning	Every visit	All ages	Weak	7.14 & 9.14 (rec.1-3)

* This grading is based on published articles and expert consensus: strong – expert consensus AND consistent evidence, moderate – expert consensus WITH inconsistent evidence AND/OR new evidence likely to support the recommendation, weak – expert majority decision WITHOUT consistent evidence. ^ If manifestation is found, please refer to the following chapters in the guideline for management and treatment of observed manifestation. MPNST = Malignant peripheral nerve sheath tumour, ANNUBP = Atypical neurofibromatous neoplasm with uncertain biologic potential. Note. MRI = magnetic resonance imaging; 18FDG PET MRI = 18F-fluorodeoxyglucose positron emission tomography magnetic resonance

ERN GENTURIS NF1 guidelines

Carton et al, 2023

UK CGG response re MRIs:

– in line with moderate risk surveillance, annual breast MRI not deliverable on NHS for all women with NF1

- Role of whole body MRI remains to be defined

paraganglioma			Consider if elective surgery requiring general anaesthesia		and 3)
Breast cancer	MRI	Yearly	30 - 50	Moderate	7.11 & 9.11 (rec. 2-3)
	Breast screening per national guideline for the general population		> 50	Moderate	7.11 & 9.11 (rec. 2-3)
Glomus tumours of the digits	Screening for symptoms and visual inspection	Every visit	All ages, clinical suspicion	Moderate (Age, weak)	7.12 & 9.12 (rec. 1-3)
Juvenile myelomonocytic leukaemia	As part of normal clinical routine: patient history and physical examination	Every visit	<12	Moderate	7.13 & 9.13 (rec. 1-2)
Psychosocial needs	Psychosocial wellbeing and neuropsychological functioning	Every visit	All ages	Weak	7.14 & 9.14 (rec.1-3)

* This grading is based on published articles and expert consensus: strong – expert consensus AND consistent evidence, moderate – expert consensus WITH inconsistent evidence AND/OR new evidence likely to support the recommendation, weak – expert majority decision WITHOUT consistent evidence. ^ If manifestation is found, please refer to the following chapters in the guideline for management and treatment of observed manifestation. MPNST = Malignant peripheral nerve sheath tumour, ANNUBP = Atypical neurofibromatous neoplasm with uncertain biologic potential. Note. MRI = magnetic resonance imaging; 18FDG PET MRI = 18F-fluorodeoxyglucose positron emission tomography magnetic resonance

Cause of Death in 80 Complex NF1 patients, Manchester

Cause of Death	Total (n)	COPD/Pneumonia	6
MPNST	**36**	Pulmonary Embolism & Deep Vein Thrombosis	3
Brain Glioma	**4**	Unknown	3
Breast Cancer	**6**	Acute ischaemic stroke/Heart Attack	2
Metastatic Spread from GIST	**2**	Found on bedroom - unresponsive, Massive retroperitoneal haemorrhage	1
Acute Myeloid Leukaemia /Acute Lymphoblastic Leukaemia	**2**	Extensive internal plexiform	1
Metastatic adenocarcinoma of small bowel/colorectal cancer	**2**	Ruptured Liver Abscess	1
Spine Glioma	**1**	Pulmonary Oedema related to Left Ventricular Hypertrophy	1
Presumed malignant mediastinal plexiform	**1**	Presumed chest infection following illness - possible progressive supranuclear palsy	1
Cholangiocarcinoma with metastases	**1**	Fatal accidental head injury	1
Large midline ganglioneuroma	**1**	Pulmonary hypertension	1
Malignant Pheochromocytoma	**1**	Presumed spinal cord injury	1
Malignancy Unspecified	**2**	Complex hydrocephalus with ventriculitis	1
Lung Cancer	**1**	sepsis secondary to a UTI	1
Liver Malignancy/Sepsis/ Respiratory Failure/ Pulmonary Oedema	**1**	Pancreatic Lesion/Obstructive Jaundice	1

MPNST

8-13% lifetime risk

Typically, young adult

Often arise in plexiforms

- Pain, growth, change in texture but can be deep and "silent"
- Can also occur in previously apparently normal tissue

Hard to detect, rapid metastasis, poor prognosis

FDG-PET helpful to detect malignant change as MR appearances non-specific

Treatment: surgery

Adjuvant radiotherapy, chemo (limited utility)

‘Red flag’ lumps/symptoms

Hard texture	Enlarging week by week	Limb weakness, numbness, incoordination
Persistent pain	Bladder or bowel change	Swallowing or breathing problems

Plexiform neurofibroma

- Definition by NCI:
  - A tumor that forms in the tissue that covers and protects the nerves. Plexiform neurofibromas can occur anywhere in the body outside of the brain and spinal cord. They can occur on the face (including around the eye), neck, arms, legs, back, chest, abdomen, and internal organs. Large tumors can cause a nerve to become thick and misshapen, which can affect the structure of nearby bone, skin, and muscle.